

Nerve Conduits for Nerve Repair or Reconstruction

D. Nicole Deal, MD
Justin W. Griffin, MD
MaCalus V. Hogan, MD

Abstract

Advances in treating peripheral nerve lesions have resulted from research in nerve regeneration and the use of biomaterials as well as synthetic materials. When direct tensionless repair of peripheral nerve lesions is not possible, nerve conduits may be used to bridge digital sensory nerve gaps of ≤ 3 cm. Nerve autograft is the benchmark for larger, longer, mixed, or motor nerve defects. Biologic, autogenous conduits—typically veins or, rarely, arteries—have demonstrated their utility in nerve gaps < 3 cm in length. Three types of bioabsorbable conduit have been approved by the US Food and Drug Administration, constructed of collagen, polyglycolic acid, or caprolactone. Caprolactone conduits have been found to be equivalent in results to autograft. Collagen conduits are next best, and polyglycolic acid conduits are functionally inferior. Further research and prospective, multicenter, large-scale trials are needed to help establish the role of synthetic, bioabsorbable conduits in peripheral nerve reconstruction.

From the Department of Orthopaedic Surgery, University of Virginia, Charlottesville, VA.

Dr. Deal or an immediate family member serves as a board member, owner, officer, or committee member of the Virginia Orthopaedic Society. Dr. Hogan or an immediate family member serves as a board member, owner, officer, or committee member of the American Academy of Orthopaedic Surgeons and the J. Robert Gladden Orthopaedic Society. Neither Dr. Griffin nor any immediate family member has received anything of value from or owns stock in a commercial company or institution related directly or indirectly to the subject of this article.

J Am Acad Orthop Surg 2012;20: 63-68

Copyright 2012 by the American Academy of Orthopaedic Surgeons.

Complex and technically demanding to manage, segmental nerve defects pose a challenge for even the most skilled surgeon. Tension-free repair of nerve lacerations is the optimal surgical treatment. When tensionless direct repair cannot be achieved, interposed nerve autograft is the benchmark.¹ However, nerve autograft results in increased surgical time and donor site morbidity, thereby justifying the search for better options. Table 1 lists the current options for bridging nerve gaps. Nonneural, hollow, tubular interposition substitutes known as nerve conduits include autogenous vein or artery grafts and synthetic tubes. Sometimes these conduits are referred to as nerve guides. Although the use of acellular cadaver nerve allografts is also increasing, clinical studies are limited. Here, we review the use of hollow,

tubular nerve conduits as a method for reconstructing nerve gaps.

History

The idea of repairing nerve gaps with hollow conduits, also known as tubulation, dates back to the late 1800s, when Gluck proposed using decalcified bone tubes for this purpose. In 1891, Bungner bridged a canine sciatic nerve gap with a segment of human brachial artery.² Platt, in 1919, reported clinical application of 6-inch vein graft for radial (musculospiral) nerve reconstruction, with no functional return.² Lundborg et al,³ in 1982, bridged rat sciatic nerves with silicone tubes, although silicone never became popular because of concerns of nerve constriction. Walton et al,⁴ in 1989, reported encouraging results in a retrospective

series of digital nerve injuries that had been reconstructed by vein conduits. In 1990, Chiu and Strauch² re-

ported a successful prospective series of autogenous vein nerve conduits (AVNCs) compared with nerve au-

tografts for digital nerve gaps ≤ 3 cm in length. Mackinnon and Dellon⁵ bridged clinical nerve gaps of ≤ 3 cm with biodegradable polyglycolic acid (PGA) in 1990. Since the early 1990s, the number of nerve conduit studies has been steadily increasing. Table 2 summarizes the data from a number of these studies.

Table 1**Options for Bridging Nerve Gaps**

Conduit Type	Bridge
Nerve	Autograft, allograft
Biologic	Vein, artery
Synthetic	Collagen (NeuraGen, Integra LifeSciences, Plainsboro, NJ; Neuroflex and NeuroMatrix, Stryker Orthopaedics, Mahwah, NJ) Polyglycolic acid (NeuroTube, Synovis Micro Companies Alliance, Birmingham, AL) Caprolactone (Neurolac Nerve Guide, Polyganics BV, Groningen, The Netherlands)

The 3-cm Limit on Nerve Conduit Length

There is a generally accepted upper limit of 3 cm on nerve conduit length. Most reported series of nerve conduits for reconstruction of digital

Table 2**Selected Clinical Nerve Conduit Studies**

Study	Conduit Type	Study Type (level of evidence)	Outcomes Measured	Conclusions
Chiu and Strauch ²	AVNC versus nerve autograft	Prospective cohort (II)	Static, moving 2PD; patient satisfaction questionnaire	AVNC comparable to nerve autografts for gaps ≤ 3 cm
Flores ⁶	AVNC	Case-control (III)	Static 2PD; SWM	AVNC of sural nerve biopsy defects did not shorten time to sensory recovery. Quality of reinnervation better than control subjects.
Rinker and Liao ⁷	AVNC versus PGA (NeuroTube ^a)	Randomized controlled trial (II)	Static, moving 2PD	No difference in sensory results between groups for repair of nerve gaps of 4–25 mm. Similar cost profile for both groups. More complications in PGA group with two extrusions requiring reoperation, although not statistically significant.
Lohmeyer et al ⁸	Collagen (NeuraGen ^b)	Prospective cohort (II)	Static 2PD	75% good to excellent results
Bertleff et al ⁹	Caprolactone (Neurolac Nerve Guide ^c) versus primary repair	Multicenter, blinded, randomized controlled trial (II)	Static, moving 1PD and 2PD	Recovery of sensation as good as that of control subjects. Time for repair greater by 14 min, and more complications reported in experimental conduit group.
Weber et al ¹⁰	PGA (NeuroTube ^a) versus primary repair (end-to-end or with nerve graft)	Multicenter, randomized, prospective controlled trial (II)	Moving 2PD	No statistically significant difference in groups in terms of overall results. Conduits superior to primary repair for gaps ≤ 4 mm, superior to nerve autograft for gaps > 8 mm.

1PD = 1-point discrimination, 2PD = 2-point discrimination, AVNC = autologous vein nerve conduit, PGA = polyglycolic acid, SWM = Semmes-Weinstein monofilament

^a Synovis Micro Companies Alliance, Birmingham, AL

^b Integra LifeSciences, Plainsboro, NJ

^c Polyganics BV, Groningen, The Netherlands

nerve defects adhere to the 3-cm limit. Mackinnon¹¹ recently reported that the indications for nerve conduits are limited to small-diameter, noncritical sensory nerves with a gap of <3 cm. Strauch et al,¹² in a rabbit peroneal nerve study that compared results of axonal regeneration using vein conduits from 1 to 6 cm in length, found excellent growth and function ≤ 3 cm, with deteriorating results at lengths >3 cm.

Investigators have attempted to overcome the 3-cm limit by experimentally inserting Schwann cells¹³ or portions of nerve or muscle within the conduit vein or tube; however, this practice has not found widespread clinical use or acceptance. The author of one study used 5-cm vein conduits for sural nerve defects following nerve biopsy and reported successful results.⁶ However, the sensory recovery of the conduits in this study was compared with that of control subjects in which the entire sural nerve had been harvested. The control subjects also obtained satisfactory recovery of protective sensation within 10 months, thus questioning the validity of the model.

Use of Conduits for Larger Diameter Nerves With Mixed Motor and Sensory Fibers

Most clinical studies of nerve conduits have targeted digital sensory nerve defects. Conduit reconstruction of larger nerves, such as the median, ulnar, or radial, has not been as well studied. Moore et al¹⁴ recently reported on four patients with unsuccessful conduit repair of larger nerves, including median, ulnar, and brachial plexus nerves. Conversely, Donoghoe et al¹⁵ reported successful repair of 3-cm median nerve gaps using PGA conduits in cable formation. Stanec and Stanec¹⁶ bridged a 2.9-cm

ulnar nerve gap with an expanded polytetrafluoroethylene tube in 1998. While anecdotal reports of larger or mixed nerve gap reconstruction with conduits have appeared, there is insufficient clinical support for the routine use of nerve conduits over nerve autografts for this indication. Although synthetic conduits are fabricated in wider diameters, this does not imply successful outcomes when they are used for larger nerves. Prospective randomized clinical trials are needed to evaluate the role of nerve conduits for mixed or purely motor nerve defects, and/or for defects >3 cm in length.

Autogenous Conduits

Autogenous conduits are usually veins (AVNCs) or, rarely, arteries. Kosutic et al¹⁷ published a case series of two homolateral digital arteries used to bridge 2- and 3-cm digital nerve defects that, at 2-year follow-up, demonstrated improved static two-point discrimination to protective levels in both patients (≤ 7 mm). The technique for AVNC involves resection back to healthy nerve, harvesting a vein twice the diameter of the nerve and 50% longer than the gap, reversing the polarity of the vein, and intussuscepting the nerve ends into the vein lumen with microsutures¹⁸ (Figure 1). Numerous clinical reports of AVNC have borne out its utility in nerve gaps <3 cm in length. Chiu and Strauch,² in a prospective study of 22 patients with painful neuromas or segmental nerve injuries of <3 cm, found that AVNCs produced clinical results similar to those of sural digital nerve grafts but inferior to those of primary end-to-end repair. The authors did not inject saline solution or heparin into the vein graft.

A recent prospective randomized clinical trial that compared AVNCs

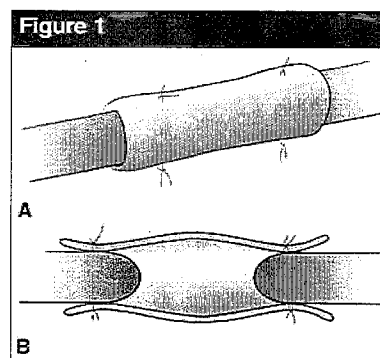


Figure 1
Illustrations of an autogenous conduit. Exterior view (A) and cross section (B) of nerve insertion into vein lumen with microsutures. (Redrawn with permission from Walton RL, Brown RE, Matory WE Jr, Borah GL, Dolph JL: Autogenous vein graft repair of digital nerve defects in the finger: A retrospective clinical study. *Plast Reconstr Surg* 1989;84[6]:944-949.)

to PGA conduits for digital nerve gaps from 4 to 25 mm found equivalent sensory results between the groups; however, there were more complications in the PGA group, including two extrusions requiring reoperation.⁷ The theoretic concern of vein graft collapse, that the vein tube will flatten and block nerve regeneration, has not been borne out clinically, and there is no clear evidence that inserting muscle or other material into the vein is superior to no interposition.

Synthetic Conduits

Three types of bioabsorbable conduits are currently approved by the US Food and Drug Administration (FDA) for use, constructed of collagen, PGA, or caprolactone. Insertion of nerve conduits requires isolation of the defect, followed by selection of the diameter and length of the tube. The technique for inserting the nerves ends into the tubes is generally as follows: The suture needle is

placed from outside the tube into the lumen. An epineural suture is placed in the nerve, and the suture is passed from inside the tube to outside the tube, thereby pulling the nerve end

into the tube. Finally, the suture is tied over the conduit⁹ (Figure 2).

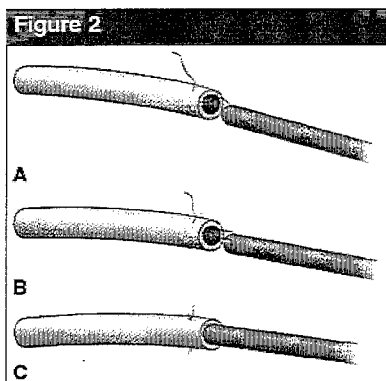
Shin et al¹⁹ compared the performance of nerve autograft to that of caprolactone, collagen, and PGA conduits in a rat sciatic nerve model with a 10-mm defect. Caprolactone conduits were found to be equivalent to autograft; collagen conduits performed next best; and PGA conduits produced greatly inferior functional results and had structurally completely collapsed by 12 weeks.

Collagen

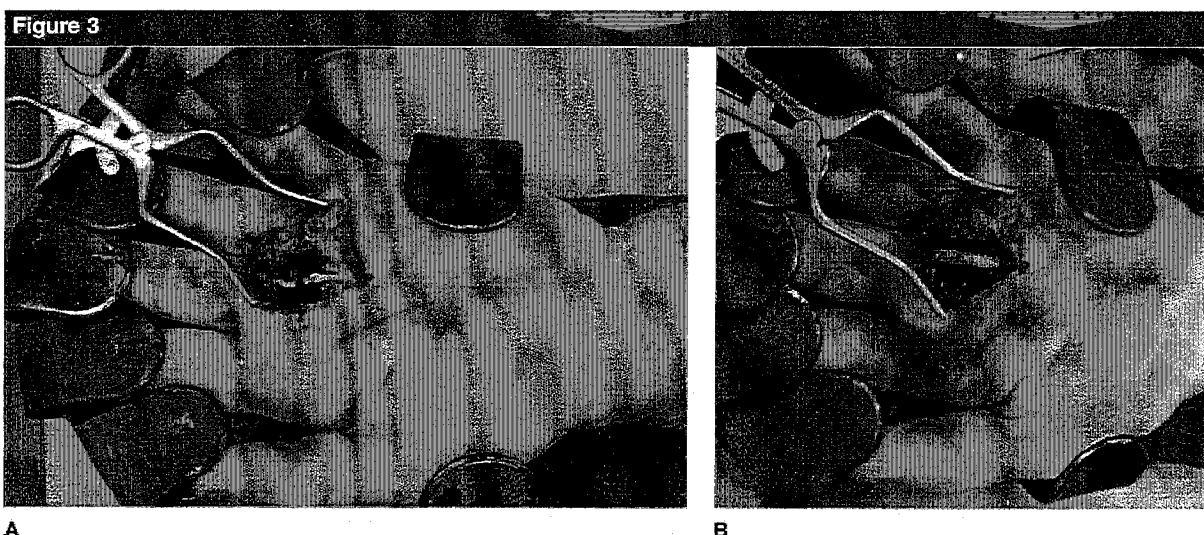
Types I and III collagen make up 49% of peripheral nerve proteins, with type I most predominant. Type I collagen is biocompatible and constitutes most conduits.²⁰ The semi-permeable nature of collagen conduits promotes diffusion and resorption by 9 months.²¹ NeuraGen (Integra LifeSciences, Plainsboro, NJ), NeuroMatrix collagen matrix (Stryker Orthopaedics, Mahwah, NJ), and Neuroflex collagen matrix (Stryker) nerve cuffs are examples of commercially available collagen conduits. Figure 3 shows intraoperative

photographs demonstrating the nerve conduit in situ used for repair of a common digital nerve.

Bushnell et al²¹ reported a 2-year follow-up of a level IV case series of 12 collagen conduit repairs of digital nerve gaps ranging in length from 10 to 12 mm. American Society for Surgery of the Hand guidelines with static two-point discrimination, Disabilities of the Arm, Shoulder, and Hand (DASH) scores, and Semmes-Weinstein testing were used to measure outcome. Of the nine patients available for follow-up, four (44%) had excellent results, four had good results (44%), and one had a fair result (11%), with average DASH score of 10. Lohmeyer et al⁸ performed a prospective cohort study involving collagen conduits to repair 12 digital nerves with an average 12.7-mm gap. One-year follow-up demonstrated 33% excellent sensory recovery and 42% good sensation, with 8% poor sensation and 8% no sensory recovery. Currently there are no randomized controlled trials examining collagen tubes. Additionally, grading of outcomes by using two-



Illustrations demonstrating insertion of nerve into nerve tubes. **A**, The needle goes from outside the tube into the lumen. **B**, An epineural stitch is performed. **C**, The stitch pulls the nerve end into the tube, and a knot is made. (Redrawn with permission from Bertleff MJ, Meek MF, Nicolai JP: A prospective clinical evaluation of biodegradable neurolac nerve guides for sensory nerve repair in the hand. *J Hand Surg Am* 2005;30[3]:513-518.)



Intraoperative photographs demonstrating common digital nerve to long/ring finger laceration before (**A**) and after (**B**) implantation of a 3-mm collagen conduit.

point discrimination is not standardized. No studies have examined motor recovery with collagen tubes.²⁰

Polyglycolic Acid

Early synthetic conduit research was performed using PGA. This tube is regarded as more flexible and porous than others, thereby allowing diffusion to aid in regeneration, with resorption occurring in 6 months.²⁰ Mackinnon and Dellon,⁵ in a prospective level IV case series, examined 15 patients undergoing secondary nerve reconstructions with PGA tubes of digital nerve gaps measuring approximately 17 mm. These authors found that 33% of patients had excellent sensory recovery, 53% good recovery, and 14% poor recovery. Sensory data was gathered using the British Medical Research Council sensory nerve grading scale with moving and static two-point discrimination. Excellent recovery was defined as static two-point discrimination ≤ 6 mm and as moving two-point discrimination ≤ 3 mm, essentially equivalent to the S4 grading system widely used (S0–S4). Good recovery was classified as static two-point discrimination between 7 and 15 mm and as moving between 4 and 7 mm. Absence of either was determined to be a poor result. Mackinnon and Dellon⁵ described extrusion in one case and concluded that PGA tubes can produce results equal to those of the classic nerve graft without donor morbidity in select sensory lesions of ≤ 3 cm.

Battiston et al²² compared PGA conduits to muscle-vein conduits and reported equivalent results. Weber et al¹⁰ conducted a level II multicenter trial comparing PGA conduits with primary repair or autograft. Surgeons randomized lacerated nerves with gaps of <3 cm (some of which had no or minimal gap) into two groups: repair with conduit

(heparin-filled) or repair without conduit, using surgical judgment as to whether to perform a primary repair or a nerve autograft. The authors reported no significant difference between the two groups as a whole. When the groups were analyzed according to nerve gap length, the authors concluded that conduits were superior to primary repair for nerve gaps of ≤ 4 mm (a gap length usually amenable to primary repair) and superior to nerve autograft for gaps ≥ 8 mm. The study design, however, included a wide range of variables that likely prohibit drawing the conclusion that conduit repair is superior to primary repair or autograft; primary repair or autograft is still considered by most to be superior to conduit repair.

Caprolactone

An aliphatic polyester, poly(DL-lactide-caprolactone), was first demonstrated in rat models to bridge 10-mm sciatic nerve gaps, with complete degradation in 1 year.²⁰ Further research has raised the issues of conduit inflexibility and unabsorbed fragments. Bertleff et al⁹ performed a multicenter blinded randomized controlled trial of 30 patients with 34 nerve injuries using Neurolac nerve tubes (Polyganics BV, Groningen, The Netherlands), which are made of caprolactone, compared with primary repair for digital nerve lacerations. Gaps of 6 to 8 mm were repaired with Neurolac tubes. Digital nerves without gaps were repaired primarily with 8-0 or 9-0 nonabsorbable suture. Pressure sensation and two-point discrimination were evaluated using a noninvasive, computer-assisted force transducer. Moving and static two-point discrimination was 7 to 10 mm for both the experimental and control groups. Time for repair was greater in the conduit group by 14 minutes; complications were greater in the Neurolac group.

This study represents preliminary evidence that caprolactone nerve tubes produce results comparable to those of primary digital nerve repair, although additional studies are needed.

Summary

Research in nerve regeneration and biomaterials has led to advancements in managing peripheral nerve lesions. When a direct tensionless repair is not possible, conduits may be used to bridge digital sensory nerve gaps of ≤ 3 cm, with nerve autograft remaining the benchmark for larger, longer, mixed, or motor nerve defects. Biologic, autogenous conduits have demonstrated their utility in nerve gaps of ≤ 3 cm. Bioabsorbable conduits of collagen, PGA, and caprolactone have been approved by the US FDA; caprolactone conduits have been found to be equivalent in results to autograft. As tissue bioengineering advances provide ways to enhance growth and increase neurotrophism, further research may expand the indications for use of nerve autografts, autogenous conduits, and synthetic conduits. There is clearly a need for prospective, multicenter, large-scale trials to aid in surgical decision making in the future of peripheral nerve reconstruction.

References

References printed in **bold type** are those published within the past 5 years.

1. Dahlin LB: Techniques of peripheral nerve repair. *Scand J Surg* 2008;97(4):310-316.
2. Chiu DT, Strauch B: A prospective clinical evaluation of autogenous vein grafts used as a nerve conduit for distal sensory nerve defects of 3 cm or less. *Plast Reconstr Surg* 1990;86(5):928-934.
3. Lundborg G, Gelberman RH, Longo FM, Powell HC, Varon S: In vivo regeneration of cut nerves encased in

- silicone tubes: Growth across a six-millimeter gap. *J Neuropathol Exp Neurol* 1982;41(4):412-422.
4. Walton RL, Brown RE, Matory WE Jr, Borah GL, Dolph JL: Autogenous vein graft repair of digital nerve defects in the finger: A retrospective clinical study. *Plast Reconstr Surg* 1989;84(6):944-949.
5. Mackinnon SE, Dellon AL: Clinical nerve reconstruction with a bioabsorbable polyglycolic acid tube. *Plast Reconstr Surg* 1990;85(3):419-424.
6. Flores LP: The use of autogenous veins for microsurgical repair of the sural nerve after nerve biopsy. *Neurosurgery* 2010;66(6 suppl operative):238-243.
7. Rinker B, Liao JY: A prospective randomized study comparing woven polyglycolic acid and autogenous vein conduits for reconstruction of digital nerve gaps. *J Hand Surg Am* 2011;36(5):775-781.
8. Lohmeyer JA, Siemers F, Machens HG, Mailänder P: The clinical use of artificial nerve conduits for digital nerve repair: A prospective cohort study and literature review. *J Reconstr Microsurg* 2009;25(1):55-61.
9. Bertleff MJ, Meek MF, Nicolai JP: A prospective clinical evaluation of biodegradable neurolac nerve guides for sensory nerve repair in the hand. *J Hand Surg Am* 2005;30(3):513-518.
10. Weber RA, Breidenbach WC, Brown RE, Jabaley ME, Mass DP: A randomized prospective study of polyglycolic acid conduits for digital nerve reconstruction in humans. *Plast Reconstr Surg* 2000;106(5):1036-1045.
11. Mackinnon SE: Technical use of synthetic conduits for nerve repair. *J Hand Surg Am* 2011;36(1):183.
12. Strauch B, Ferder M, Lovelle-Allen S, Moore K, Kim DJ, Llena J: Determining the maximal length of a vein conduit used as an interposition graft for nerve regeneration. *J Reconstr Microsurg* 1996;12(8):521-527.
13. Strauch B, Rodriguez DM, Diaz J, Yu HL, Kaplan G, Weinstein DE: Autologous Schwann cells drive regeneration through a 6-cm autogenous venous nerve conduit. *J Reconstr Microsurg* 2001;17(8):589-595.
14. Moore AM, Kasurthi R, Magill CK, et al: Limitations of conduits in peripheral nerve repairs. *Hand (N Y)* 2009;4(2):180-186.
15. Donoghoe N, Rosson GD, Dellon AL: Reconstruction of the human median nerve in the forearm with the Neurotube. *Microsurgery* 2007;27(7):595-600.
16. Stanec S, Stanec Z: Ulnar nerve reconstruction with an expanded polytetrafluoroethylene conduit. *Br J Plast Surg* 1998;51(8):637-639.
17. Kosutic D, Krajnc I, Pejckovic B, Solman L: Autogenous digital artery graft for repair of digital nerve defects in emergency hand reconstruction: Two-year follow-up. *J Plast Reconstr Aesthet Surg* 2009;62(4):553.
18. Strauch B: Use of nerve conduits in peripheral nerve repair. *Hand Clin* 2000;16(1):123-130.
19. Shin RH, Friedrich PF, Crum BA, Bishop AT, Shin AY: Treatment of a segmental nerve defect in the rat with use of bioabsorbable synthetic nerve conduits: A comparison of commercially available conduits. *J Bone Joint Surg Am* 2009;91(9):2194-2204.
20. Meek MF, Coert JH: US Food and Drug Administration/Conformit Europe-approved absorbable nerve conduits for clinical repair of peripheral and cranial nerves. *Ann Plast Surg* 2008;60(4):466-472.
21. Bushnell BD, McWilliams AD, Whitener GB, Messer TM: Early clinical experience with collagen nerve tubes in digital nerve repair. *J Hand Surg Am* 2008;33(7):1081-1087.
22. Battiston B, Geuna S, Ferrero M, Tos P: Nerve repair by means of tubulization: Literature review and personal clinical experience comparing biological and synthetic conduits for sensory nerve repair. *Microsurgery* 2005;25(4):258-267.