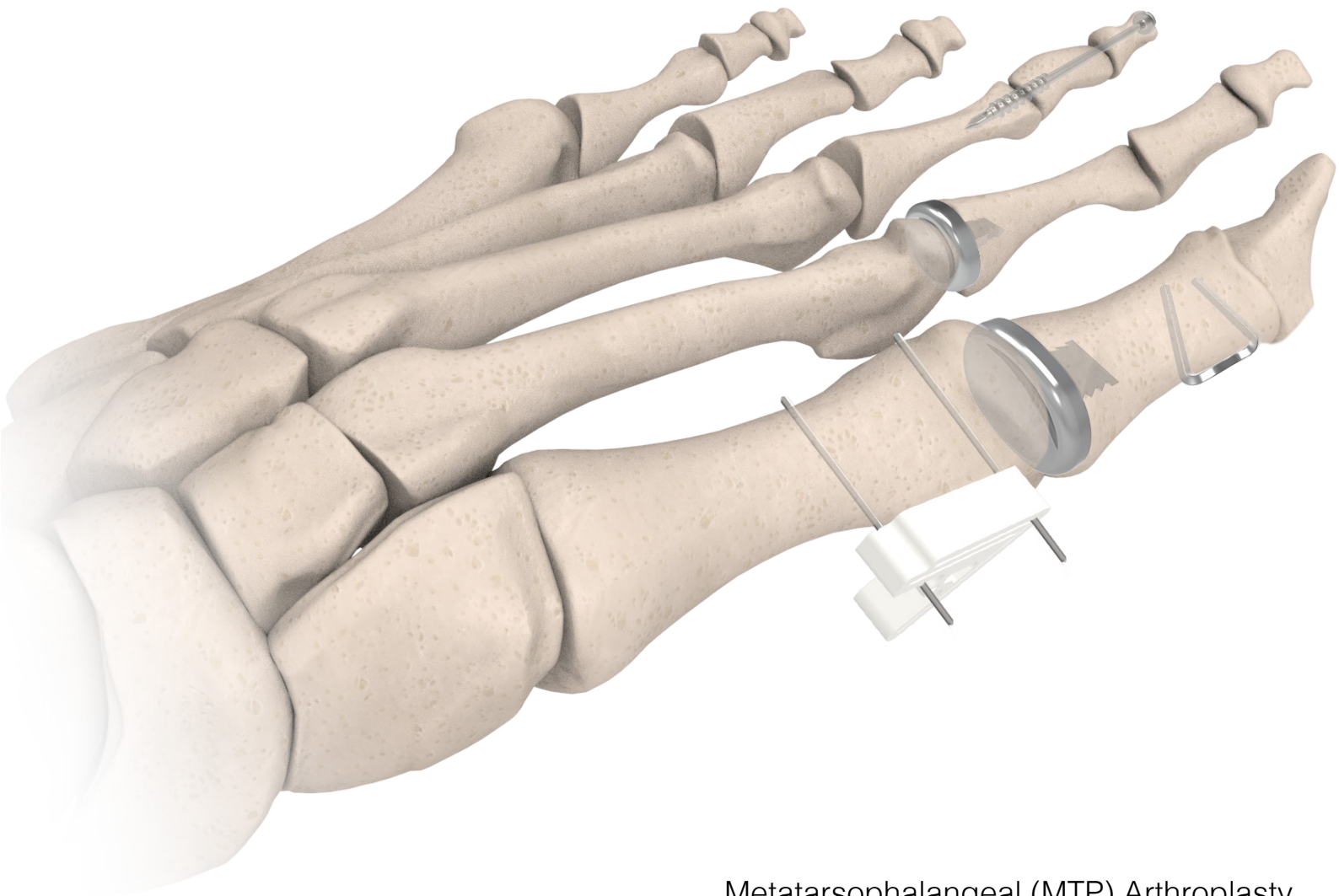
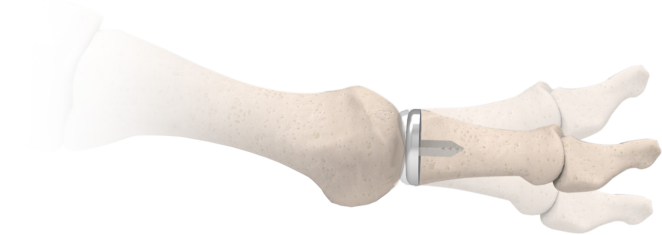

Forefoot Solutions



- Metatarsophalangeal (MTP) Arthroplasty
- Hallux Valgus correction
- Hammertoe correction (PIPJ/DIPJ)
- Medial Closing Wedge Osteotomy (Akin)

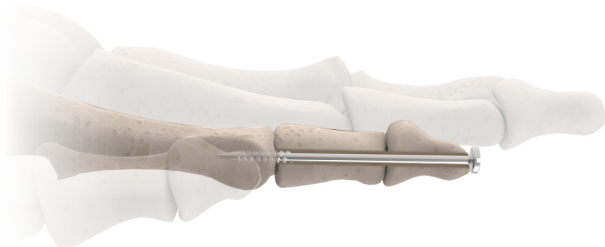
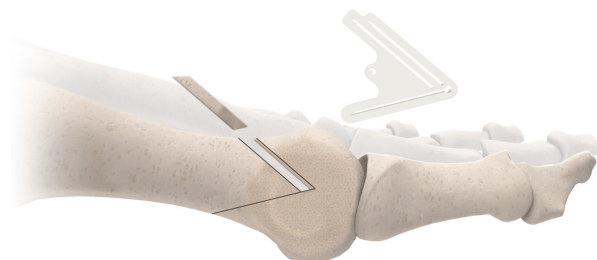
Metatarsophalangeal (MTP) Arthroplasty

The BioPro First MPJ Hemi Implant is the globally trusted solution for the treatment of hallux rigidus/limitus. Now in clinical use for over 65 years¹, the First MPJ Hemi Implant continues to demonstrate improved motion, long term survivorship and pain relief.^{1,2,3} Also available is a newly designed HemiEDGE™ implant for improved stability and our Lesser MPJ Hemi Implant, offering 9 standard sizes for the lesser digits.

Hallux Valgus correction

The Accu-Cut® Osteotomy Guide System provides precise and repeatable osteotomies⁴ including: Chevron, Scarf, Youngswick, and DMAA/PASA. Our Go-EZ and HBS cannulated screws allow for secure fixation once the desired osteotomy has been performed.

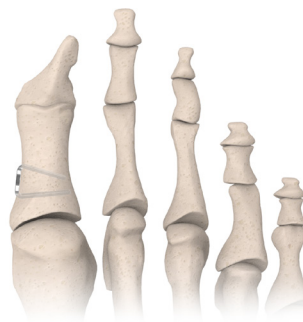


Hammertoe correction (PIPJ/DIPJ)

The Digital Compression Screw is a solid, stainless steel screw specifically designed to address digital fusions. The 1.5mm and 1.8mm diameters range from 20mm to 55mm in length, allowing for fusion of the DIPJ, PIPJ, or both.

Medial Closing Wedge Osteotomy (Akin)

The Memory Staple is an ideal solution for fixation of a medial closing wedge osteotomy (Akin). The Nitinol staple activates at patient's body temperature, allowing for continuous compression across the fusion site. Our 7x5mm and 9x7mm staples are specifically designed to address fusions in the small bones of the forefoot.



Visit www.bioproimplants.com or call us at (810) 982-7777

1. Juan C. Goez, DPM, Charles O. Townley MD, Warren Taranow, DO. An Update on the Metallic Hemiarthroplasty Resurfacing Prosthesis for the Hallux. Presented at the 56th Annual Meeting and Scientific Seminar of the American College of Foot and Ankle Surgeons. Orlando FL February 1998
2. Townley, MD, Taranow, DO. A metallic hemiarthroplasty resurfacing prosthesis for the hallux metatarsophalangeal joint. Foot & Ankle International 1994;15(11):575-80
3. Christine C. Salonga, DPM, David C. Novicki, DPM, FACFAS, Martin M. Pressman, DPM, FACFAS, D. Scot Malay, DPM, MSCE, FACFAS. A Retrospective Cohort Study of the BioPro Hemiarthroplasty Prosthesis. The Journal of Foot & Ankle Surgery 49 (2010) 331-339
4. Evaluation of surgical experience and the use of an osteotomy guide on the apical angle of an Austin osteotomy The Foot, Volume 18, Issue 3, Pages 159-164 V.J. Hetherington, J.S. Kawalec-Carroll, J. Melillo-Kroleski, T. Jones, M. Melillo, N. McFarland, M. Blazer, J.A. Favazzo



+1-810-982-7777
 info@bioproimplants.com
 2929 Lapeer Road
 Port Huron, MI 48060

