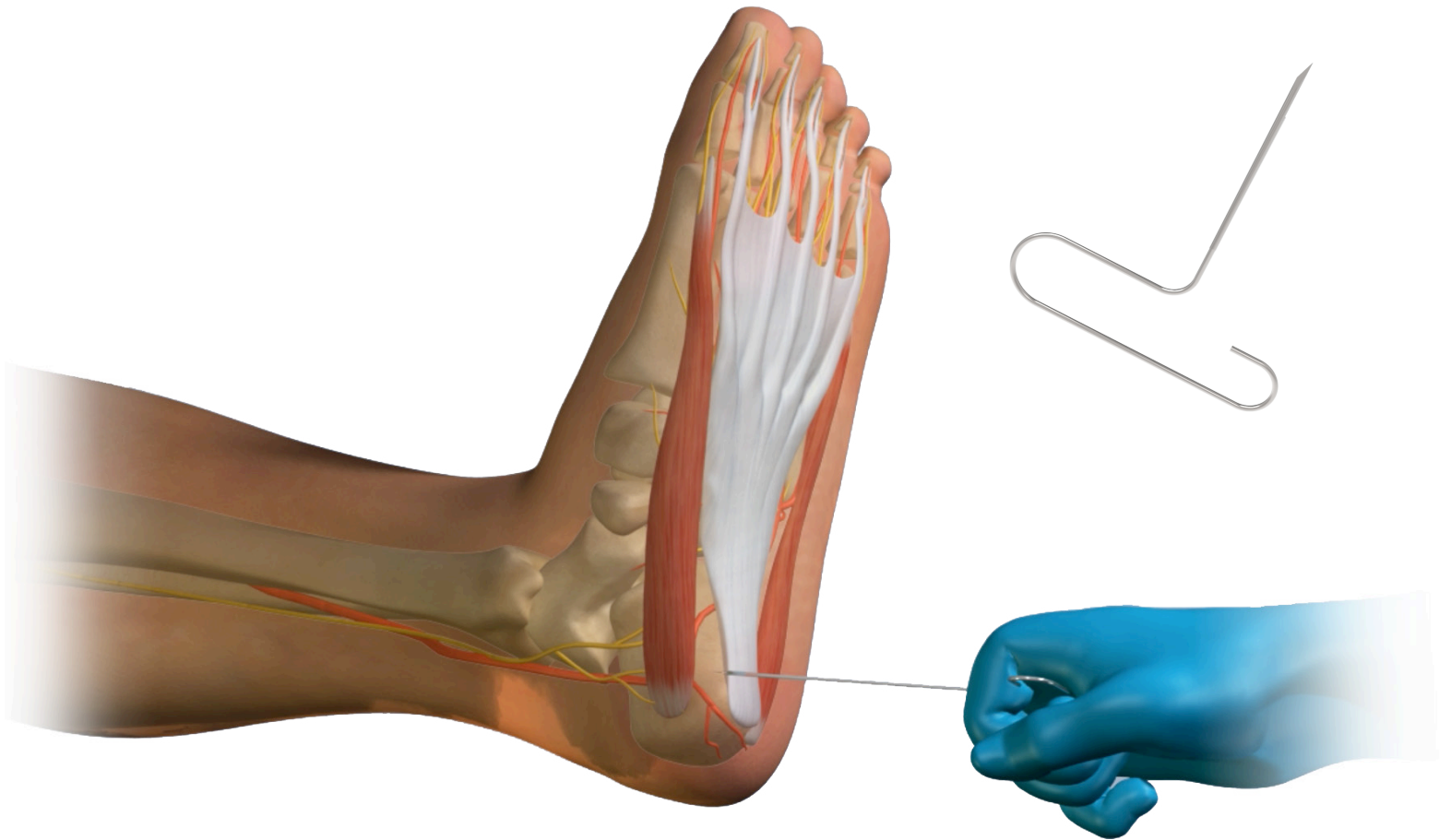


Fasciotome™

A percutaneous solution for tenotomies and plantar fasciotomies.¹

The BioPro Fasciotome™ is intended to assist surgeons in percutaneous tenotomies and plantar fasciotomies. The Fasciotome features an extremely sharp, one-sided blade for effortless releases; provided in convenient single-use, sterile packs.



Fasciotome™

Percutaneous medial fascial release findings.

- 86 percent good to excellent result with a two-year follow-up²
- Minimally invasive option for plantar fascia release^{1,2}
- Faster recovery¹
- Less scarring
- Can be performed in-office

Step One

After an appropriate local block has been administered, locate the medial band of the plantar fascia by dorsiflexing the foot and great toe. This allows you to palpate the medial band in the arch area and follow it back proximally to the heel. (Fig 1)

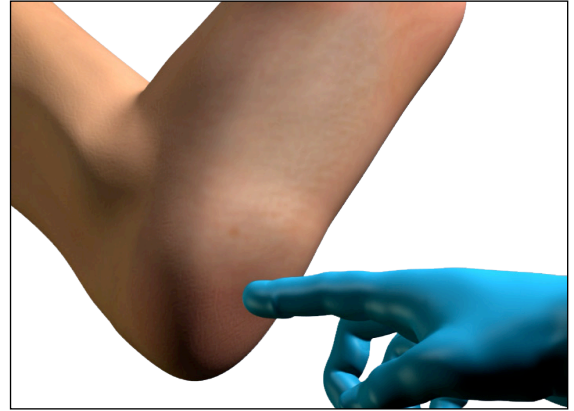


Fig 1

Step Two

The percutaneous portal is located by bisecting the medial malleolus and drawing the bisection line down to the medial plantar area of the foot. (Fig 2) This approach offers a safe location for percutaneous release of the fascia by staying proximal to the medial and lateral plantar nerves.

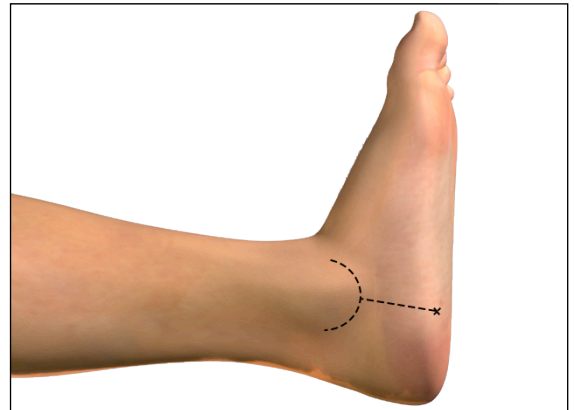


Fig 2

Note: Ultrasound imaging can aid in the accurate placement of the percutaneous fasciotomy if desired.

Step Three

The foot should be appropriately prepped and draped. Utilizing the Fasciotome™ the skin is penetrated and the Fasciotome™ is brought in contact with the medial band of the plantar fascia, cutting the medial band of the plantar fascia.(Fig 3)

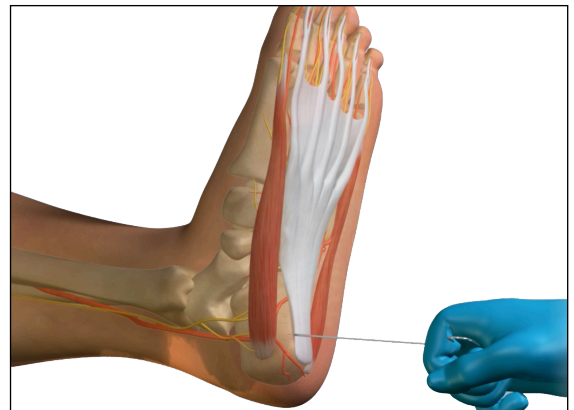


Fig 3

Step Four

After the Fasciotome™ releases the medial band, there will be a loss of the prominence of the medial band to the fascia in the arch area.

Step Five

No suturing of the portal is necessary, dry sterile dressing, and a modified Campbell's rest strapping of the foot and ankle is recommended. Patient may immediately weight bear.

This technique only represents an overview of the surgical technique for the BioPro Fasciotome. A surgeon must always rely on his or her own professional clinical judgment when performing a surgical procedure.

Visit www.bioproimplants.com or call us at (810) 982-7777

1. A Retrospective Comparison of Percutaneous Plantar Fasciotomy and Open Plantar Fasciotomy with Heel Spur Resection Fallat, Lawrence M. et al. The Journal of Foot and Ankle Surgery , Volume 52 , Issue 3 , 288 - 290
2. Brian McCurdy. (2013, July). How Effective Is Percutaneous Plantar Fasciotomy? Retrieved from <https://www.podiatrytoday.com/july-2013>



+1-810-982-7777
 info@bioproimplants.com
 2929 Lapeer Road
 Port Huron, MI 48060

